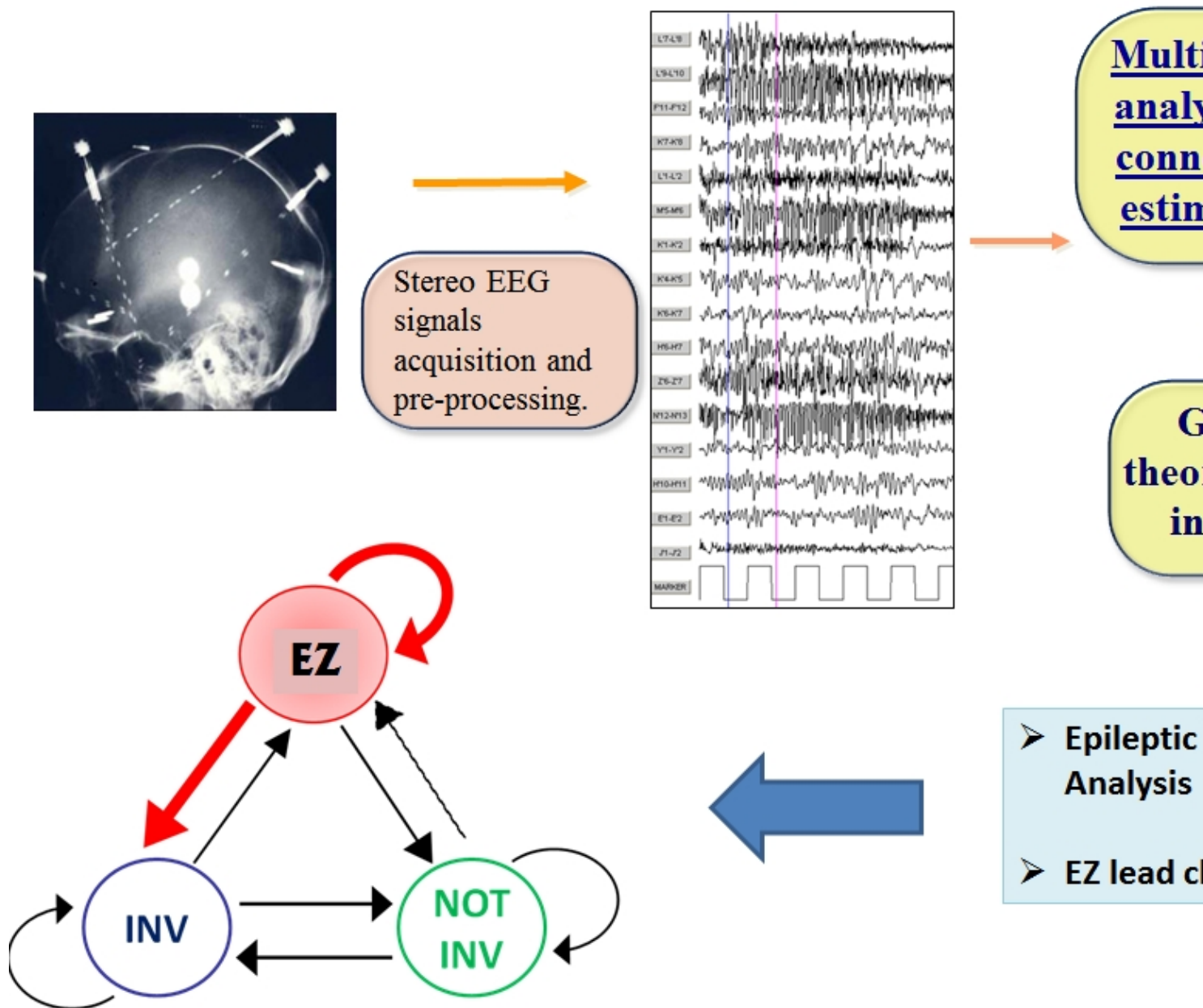


Identification of the epileptogenic network in patients with focal cortical dysplasia



The leading role of the lesional zone may account for the good post-surgical outcome of patients with